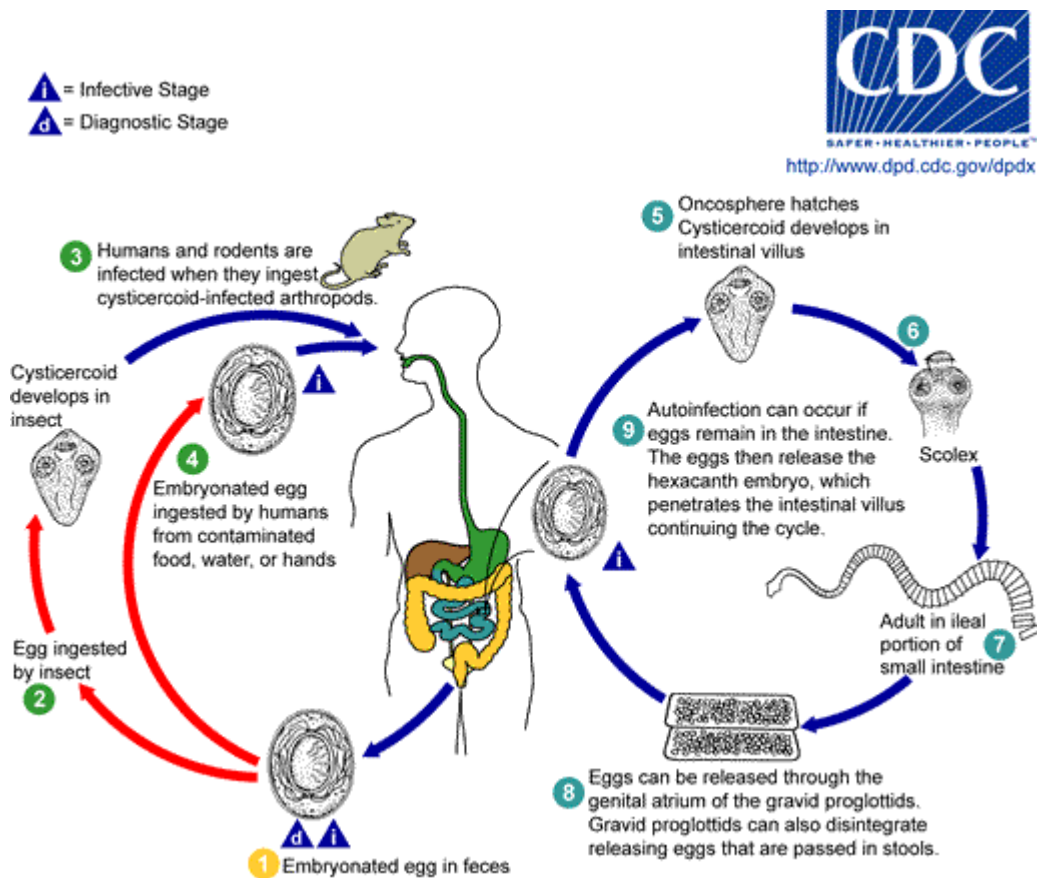


Hymenolepiasis

Causal Agents:

Hymenolepiasis is caused by two cestodes (tapeworm) species, *Hymenolepis nana* (the dwarf tapeworm, adults measuring 15 to 40 mm in length) and *Hymenolepis diminuta* (rat tapeworm, adults measuring 20 to 60 cm in length). *Hymenolepis diminuta* is a cestode of rodents infrequently seen in humans and frequently found in rodents.

Life Cycle:



Eggs of *Hymenolepis nana* are immediately infective when passed with the stool and cannot survive more than 10 days in the external environment **1**. When eggs are ingested by an arthropod intermediate host **2** (various species of beetles and fleas may serve as intermediate hosts), they develop into cysticercoids, which can infect humans or rodents upon ingestion **3** and develop into adults in the small intestine. A morphologically identical variant, *H. nana* var. *fraterna*, infects rodents and uses arthropods as intermediate hosts. When eggs are ingested **4** (in contaminated food or water or from hands contaminated with feces), the oncospheres contained in the eggs are released. The oncospheres (hexacanth larvae) penetrate the intestinal villus and develop into cysticercoid larvae **5**. Upon rupture of the villus, the cysticercoids return to the intestinal lumen, evaginate their scoleces **6**, attach to the intestinal mucosa and develop into adults that reside in

Geographic Distribution:

Hymenolepis nana is the most common cause of all cestode infections, and is encountered worldwide. In temperate areas its incidence is higher in children and institutionalized groups. *Hymenolepis diminuta*, while less frequent, has been reported from various areas of the world.

Clinical Features:

Hymenolepis nana and *H. diminuta* infections are most often asymptomatic. Heavy infections with *H. nana* can cause weakness, headaches, anorexia, abdominal pain, and diarrhea.

Laboratory Diagnosis:

The diagnosis depends on the demonstration of eggs in stool specimens. Concentration techniques and repeated examinations will increase the likelihood of detecting light infections.

Diagnostic findings

- Microscopy
- Macroscopic (gross) observations
- Morphologic comparison with other intestinal parasites

Treatment:

Praziquantel* is the drug of choice.

* This drug is approved by the FDA, but considered investigational for this purpose.